

Image Article

Behçet's Disease Presenting as Cerebral Venous Thrombosis

Pratibha Prasad^{1*} and Prem Shanker Verma²¹Department of Neurology, Dr. S.N. Medical College, Rajasthan University of Health Science, Jodhpur, Rajasthan, India²Department of Neurosurgery, Institute of Medical Sciences BHU, Varanasi, Uttar Pradesh, India

*Correspondence: Pratibha Prasad, Department of Neurology, Dr.S.N. Medical College, Rajasthan University of Health Science, Jodhpur, Rajasthan, India

Received date: Jan 02, 2023; Accepted date: Jan 11, 2023; Published date: Jan 28, 2023

Citation: Prasad, Pratibha and Prem Shanker Verma. "Behçet's Disease Presenting as Cerebral Venous Thrombosis. J Neu 1,1.

Copyright: © 2023 S Prasad P, et al. All intellectual property rights, including copyrights, trademarks rights and database rights with respect to the information, texts, images, logos, photographs and illustrations on the website and with respect to the layout and design of the website are protected by intellectual property rights and belong to Publisher or entitled third parties. The reproduction or making available in any way or form of the contents of the website without prior written consent from Publisher is not allowed.

CLINICAL IMAGE

Occurrence of Cerebral Venous Thrombosis (CVT) as a presenting symptom of Behçet's Disease (BD) is quite uncommon [1]. Few cases regarding the first presentation of BD with CVT are reported [2-5] but hardly any case in Indian perspective. Therefore, we report cerebral venous thrombosis as the initial presentation of Behçet's disease in a 32-year-old immunocompetent Indian male. He presented with severe headache and vomiting with gradual progressive painless loss of vision in both eyes (right > left) since one and half month. Past history revealed recurrent oral and genital ulcers in last seven months. Neurological examination revealed bilateral papilledema and right sixth cranial nerve palsy. Ophthalmoscopy revealed panuveitis with papilloedema in right eye (Figure 1A) more than left eye (Figure 1B). MRV showed right transverse sinus and superior sagittal sinus thrombosis (Figure 2). Thrombophilia screening showed positivity in HLAB51. Pathergy test was positive. A diagnosis of behcet disease was made. Patient was treated with anti-coagulant therapy, immunosuppressive drug and acetazolamide and was in follow up for one year with no recurrent symptoms. Thus there is a need to increase the awareness of neuro behcet's disease whenever headache due to CVT is associated with oral and genital ulcers.

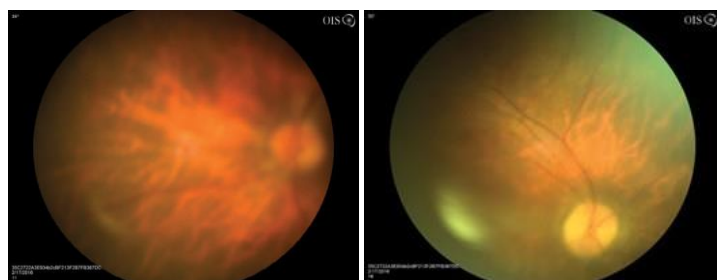


Figure 1. Ophthalmoscopy showing panuveitis with papilloedema in right eye (A) more than left eye (B).

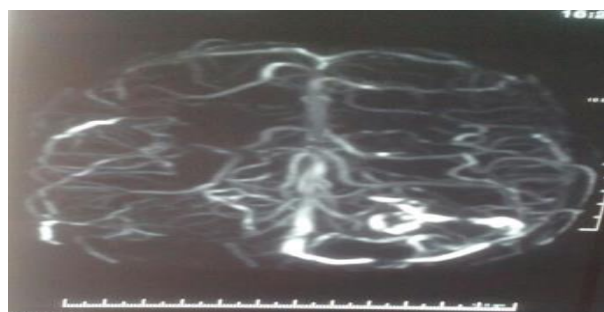


Figure 2. MRV showing right transverse sinus and superior sagittal sinus thrombosis.

REFERENCES

1. Aguiar de Sousa, D, T Mestre and J M Ferro. "Cerebral venous thrombosis in Behçet's disease: a systematic review." *J Neurol* 258(2011): 719-727.
2. Ascaso, FJ, A Rodriguez and JA Cristóbal. "Cranial hypertension as first manifestation of Behçet's disease: a case report." *Doc Ophthalmol* 105(2002): 291-299.
3. Chaloupka, Karla, Edoardo Baglivo, Michael Hofer and Carlo Chizzolini, et al. "Cerebral sinus thrombosis in Behçet disease: case report and review of the literature." *Klin Monbl Augenheilkd* 220(2003):186-188.
4. Rahil, Ali Ibrahim, Mehdi Errayes and Khaled M Salem. "Cerebral venous thrombosis as the initial presentation of Behcet's disease." *Chang Gung Med J* 32(2009): 220-223.
5. Can, Emrah, Bülent Kara, Ayper Somer and Melike Keser, et al. "Neuro- Behçet disease presenting as secondary pseudotumor syndrome: case report." *Eur J Paediatr Neurol* 10(2006): 97-99.