

## Papulo Squamous Eruptions of Human Penis, four Cases Reported

Mohammed Abdul Qader AlMalmi \*

\* Department of Dermatology and Venereology, Al-Kuwait University Hospital, Sana'a University Medical School, Sana'a, Republic of Yemen

### CASE REPORT

#### ABSTRACT

**Background:** Noninfectious lesions may be classified as inflammatory and papulo squamous (e.g., psoriasis, lichen planus, lichen nitidus and lichen sclerosis et atrophicus).

**Objectives:** To identify the chronic skin disease of human penis.

**Patients and methods:** Forty years old four male's Yemeni patients presented with non-itchy and itchy, scaly and non-scaly erythematous papules skin eruptions in the shaft and glans penis. The duration was one year. Skin biopsy was done and examined histopathological [1-8]. They treated with topical steroids.

**Results:** The clinical data and the investigations showed four patients had psoriasis, lichen planus, lichen nitidus and lichen sclerosus et atrophicus of their shaft and glans penis.

**Conclusion:** Papulo squamous eruptions of human penis are common skin diseases in the republic of Yemen [9].

#### KEYWORDS

Human penis, Squamous eruptions, Psoriasis, Epidermis

**Correspondence to:** Dr. Mohammed Abdul Qader AlMalmi, Department of Dermatology and Venereology, Al-Kuwait University Hospital, Sana'a University Medical School, Sana'a, Republic of Yemen, Email: maqma1952@gmail.com

**Received:** March 21, 2024, **Accepted:** April 12, 2024, **Published:** May 15, 2024

**DOI:** 10.1042/JCTCS.6.1.0013

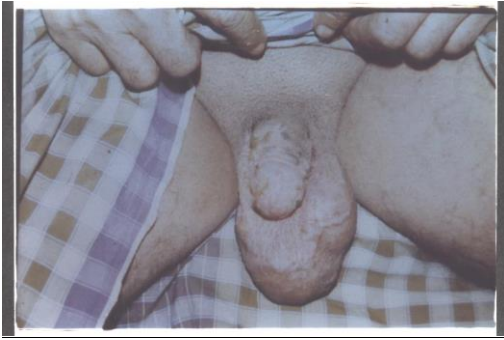**Citation:** Mohammed Abdul Qader AlMalmi, 2024, Papulo Squamous Eruptions of Human Penis, four Cases Reported. JCTCS. Vol 6.

**Copyright:** © 2024, Mohammed Abdul Qader AlMalmi. All intellectual property rights, including copyrights, trademarks rights and database rights with respect to the information, texts, images, logos, photographs and illustrations on the website and with respect to the layout and design of the website are protected by intellectual property rights and belong to Probe Publisher or entitled third parties. The reproduction or making available in any way or form of the contents of the website without prior written consent from Probe Publisher is not allowed.

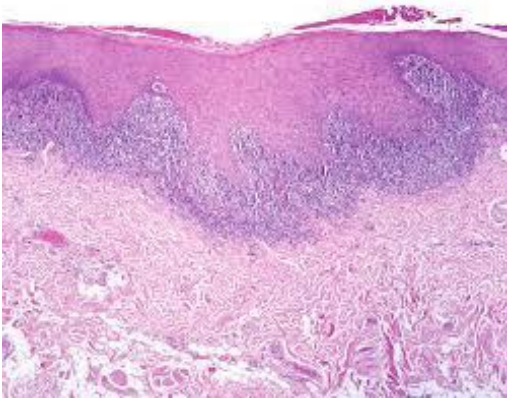
#### INTRODUCTION

Histopathological findings of 10 representative features of psoriasis were investigated on each slide: regular elongation of the rete ridges, elongation of the dermal papillae, edema of the dermal papillae, dilated blood vessels, thinning of the suprapapillary plate, intermittent parakeratosis, absence of a granular (Figure 4) [10-17]. Histology of lichen planus. There is irregular epidermal hyperplasia forming a characteristic saw-tooth appearance with wedge-shaped hypergranulosis. The basal layer of the epidermis exhibits vacuolar degeneration with typically prominent necrosis of individual keratinocytes (Figure 2). Lichen sclerosus et atrophicus, the collagen fibers appeared green in the reticular dermis at both early and late stage [18-30]. In the papillary dermis the fibers appeared orange at an early stage and greenish orange at a late **stage** (Figure 8). The histology of lichen nitidus is very typical and described as the 'claw and ball' appearance: Focal dense lymphohistiocytic infiltrate in the upper dermis very close to the epidermis. Langhans giant cells are often present in the infiltrate [31-40].

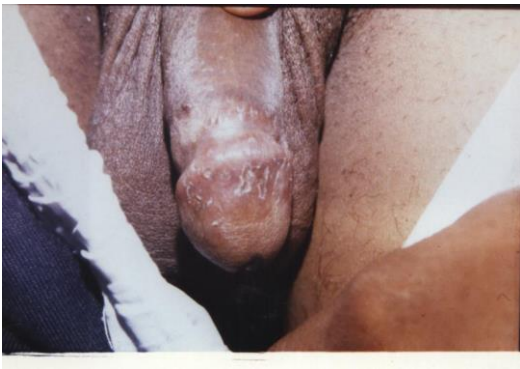Rete ridges of the epidermis are elongated and 'clutch' the infiltrate (Figure 6). Psoriasis. Pruritus Red or salmon-colored, papulosquamous, circinate plaques that are often associated with white or silvery scales; usually systemic (Figure 3). Lichen planus Pruritus, soreness Flat-topped, polygonal, violaceous papules; often extragenital (Figure 1). Lichen sclerosus Phimosis, painful erections, obstructive voiding, itching, pain, bleeding Hypopigmented, thinned, phimotic prepuce; texture similar to cellophane; isolated to prepuce and glans penis (Figure 7). Lichen nitidus Asymptomatic Pinhead-sized, hypopigmented papules; often extragenital (Figure 5). Psoriasis Topical corticosteroids Vitamin D3 analogues, tacrolimus (Protopic), or pimecrolimus (Elidel)) [41-49]. Lichen planus Topical corticosteroids. Lichen sclerosus et atrophicus. Topical corticosteroids. Lichen nitidus Observation Topical corticosteroids, vitamin A analogues, cyclosporine (Sandimmune), itraconazole (Sporanox), phototherapy.



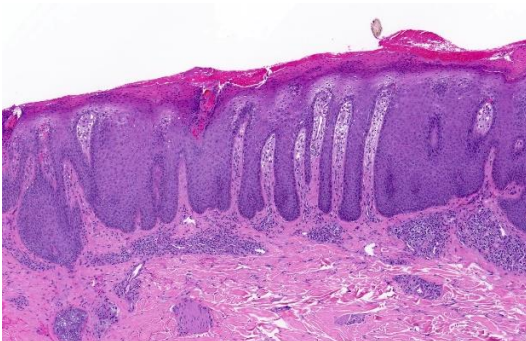
**Figure 1:** Erosive chronic lichen planus.



**Figure 2:** Histopathology of lichen planus.



**Figure 3:** Erosive chronic psoriasis.



**Figure 4:** Histopathology of psoriasis.

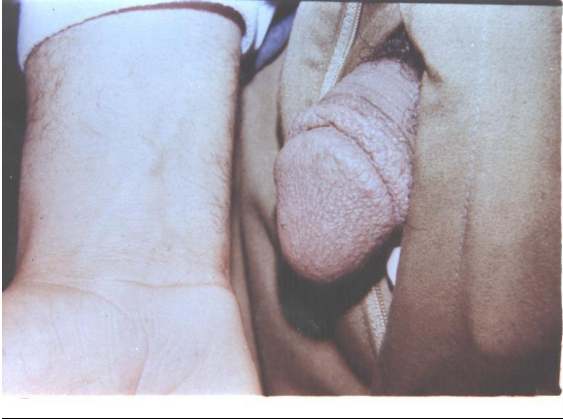

Figure 5: Lichen nitidus.

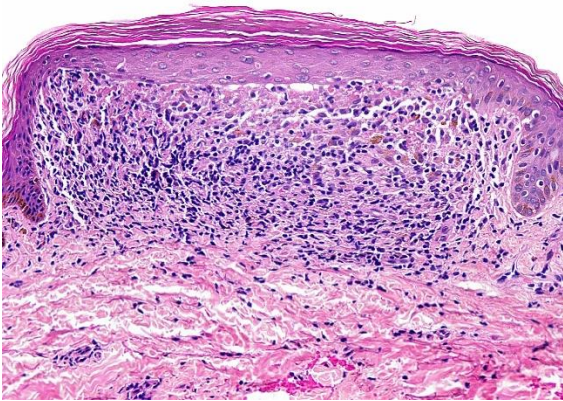
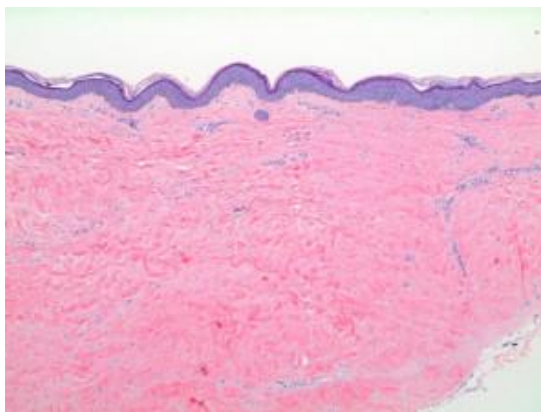


Figure 6: Histopathology of lichen nitidus.

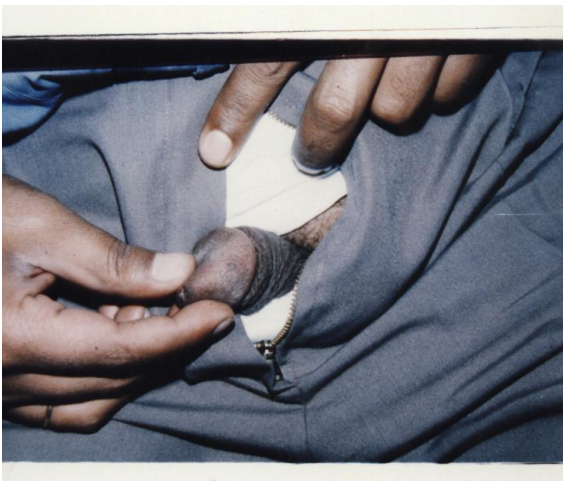

Figure 7: Lichen sclerosus et atrophicus.



**Figure 8:** Histopathology of lichen sclerosus et atrophicus.

### REFERENCES

- 1) Teichman JM, Weiss BD, Solomon D. Urological needs assessment for primary care practice: implications for undergraduate medical education. *J Urol.* 1999, 161:1282-1285.
- 2) Griffiths CE, Barker JN. Pathogenesis and clinical features of psoriasis. *Lancet.* 2007, 370:263-271.
- 3) Farber EM, Nall L. Genital psoriasis. *Cutis.* 1992, 50:263-266.
- 4) Gudjonsson JE, Elder JT. Psoriasis: epidemiology. *Clin Dermatol.* 2007, 25:535-546.
- 5) MacDonald A, Burden AD. Psoriasis: advances in pathophysiology and management. *Postgrad Med J.* 2007, 83:690-697.
- 6) Buechner SA. Common skin disorders of the penis. *BJU Int.* 2002, 90:498-506.
- 7) Quan MB, Ruben BS. Pustular psoriasis limited to the penis. *Int J Dermatol.* 1996, 35:202-204.
- 8) Menter A, Griffiths CE. Current and future management of psoriasis. *Lancet.* 2007, 370:272-284.
- 9) van de Kerkhof PC, Vissers WH. Established treatments of psoriasis. *Curr Drug Targets Inflamm Allergy.* 2004, 3:145-156.
- 10) Lebwohl M. A clinician's paradigm in the treatment of psoriasis. *J Am Acad Dermatol.* 2005, 53:S59-69.
- 11) Kalb RE, Bage J, Korman NJ, Lebwohl MG, Young M, et al. Treatment of intertriginous psoriasis: from the Medical Board of the National Psoriasis Foundation. *J Am Acad Dermatol.* 2009, 60:120-124.
- 12) Val I, Almeida G. An overview of lichen sclerosus. *Clin Obstet Gynecol.* 2005, 48:808-817.
- 13) Funaro D. Lichen sclerosus: a review and practical approach. *Dermatol Ther.* 2004, 17:28-37.
- 14) Tasker GL, Wojnarowska F. Lichen sclerosus. *Clin Exp Dermatol.* 2003, 28:128-133.
- 15) Peterson AC, Palminteri E, Lazzeri M, Guanzoni G, Barbagli G, et al. Heroic measures may not always be justified in extensive urethral stricture due to lichen sclerosus (balanitis xerotica obliterans). *Urol.* 2004, 64:565-568.
- 16) Yesudian PD, Sugunendran H, Bates CM, O'Mahony C. Lichen sclerosus. *Int J STD AIDS.* 2005, 16:465-473.
- 17) Wallace HJ. Lichen sclerosus et atrophicus. *Trans St Johns Hosp Dermatol Soc.* 1971, 57:9-30.
- 18) Neill SM, Tatnall FM, Cox NH for the British Association of Dermatologists. Guidelines for the management of lichen sclerosus. *Br J Dermatol.* 2002, 147:640-649.
- 19) Bunker CB. Topics in penile dermatology. *Clin Exp Dermatol.* 2001, 26:469-479.
- 20) Pugliese JM, Morey AF, Peterson AC. Lichen sclerosus: review of the literature and current recommendations for management. *J Urol.* 2007, 178:2268-2276.
- 21) Schiller PI, Itin PH. Angiokeratomas: an update. *Dermatol.* 1996, 193:275-282.
- 22) Malalasekera AP, Goddard JC, Terry TR. Angiokeratoma of Fordyce simulating recurrent penile cancer. *Urol.* 2007, 69:576-e14.
- 23) Leis-Dosil VM, Alijo-Serrano F, Aviles-Izquierdo JA, Lazaro-Ochaita P, Lecona-Echeverria M. Angiokeratoma of the glans penis: clinical, histopathological and dermoscopic correlation. *Dermatol Online J.* 2007, 13:19.
- 24) Fordyce J. Angiokeratoma of the scrotum. *J Cutan Dis.* 1896, 14:81-89.
- 25) Imperial R, Helwig EB. Angiokeratoma. A clinicopathological study. *Arch Dermatol.* 1967, 95:166-175.
- 26) Bechara FG, Huesmann M, Stücker M, Altmeyer P, Jansen T. An exceptional localization of angiokeratoma of Fordyce on the glans penis. *Dermatol.* 2002, 205:187-188.
- 27) Gioglio L, Porta C, Moroni M, Nastasi G, Gangarossa I. Scrotal angiokeratoma (Fordyce): histopathological and ultrastructural findings. *Histol Histopathol.* 1992, 7:47-55.

- 28) Orteu CH, Jansen T, Lidove O, Jaussaud R, Hughes DA, et al.; for the FOS Investigators. Fabry disease and the skin: data from FOS, the Fabry outcome survey. *Br J Dermatol.* 2007, 157:331-337.
- 29) Lapidoth M, Ad-El D, David M, Azaria R. Treatment of angiokeratoma of Fordyce with pulsed dye laser. *Dermatol Surg.* 2006, 32:1147-1150.
- 30) Gorse SJ, James W, Murison MS. Successful treatment of angiokeratoma with potassium tritanyl phosphate laser. *Br J Dermatol.* 2004, 150:620-622.
- 31) Davis DA, Skidmore RA, Woosley JT. Lichen nitidus. *Urol.* 1996, 47:573.
- 32) Wright S. Successful treatment of lichen nitidus. *Arch Dermatol.* 1984, 120:155-156.
- 33) Kim YC, Shim SD. Two cases of generalized lichen nitidus treated successfully with narrow-band UV-B phototherapy. *Int J Dermatol.* 2006, 45:615-617.
- 34) Porter WM, Bunker CB. The dysfunctional foreskin. *Int J STD AIDS.* 2001, 12:216-220.
- 35) Altman J, Perry HO. The variations and course of lichen planus. *Arch Dermatol.* 1961, 84:179-191.
- 36) Horan DB, Redman JF, Jansen GT. Papulosquamous lesions of glans penis. *Urol.* 1984, 23:1-4.
- 37) Rosen T, Brown TJ. Genital ulcers. Evaluation and treatment. *Dermatol Clin.* 1998, 16:673-685.
- 38) Cribier B, Frances C, Chosidow O. Treatment of lichen planus. An evidence-based medicine analysis of efficacy. *Arch Dermatol.* 1998, 134:1521-1530.
- 39) Porter WM, Dinneen M, Hawkins DA, Bunker CB. Erosive penile lichen planus responding to circumcision. *J Eur Acad Dermatol Venereol.* 2001, 15:266-268.
- 40) Singh S, Bunker C. Male genital dermatoses in old age. *Age Ageing.* 2008, 37:500-504.
- 41) Gerber GS. Carcinoma in situ of the penis. *J Urol.* 1994, 151:829-833.
- 42) Mosconi AM, Roila F, Gatta G, Theodore C. Cancer of the penis. *Crit Rev Oncol Hematol.* 2005, 53:165-177.
- 43) Murray WJ, Fletcher MS, Yates-Bell AJ, Pryor JP, Darby AJ, et al. Plasma cell balanitis of Zoon. *Br J Urol.* 1986, 58:689-691.
- 44) Retamar RA, Kien MC, Chouela EN. Zoon's balanitis: presentation of 15 patients, five treated with a carbon dioxide laser. *Int J Dermatol.* 2003, 42:305-307.
- 45) Weyers W, Ende Y, Schalla W, Diaz-Cascajo C. Balanitis of Zoon: a clinicopathologic study of 45 cases. *Am J Dermatopathol.* 2002, 24:459-467.
- 46) Lucky MA, Rogers B, Parr NJ. Referrals into a dedicated British penile cancer centre and sources of possible delay. *Sex Transm Infect.* 2009, 85:527-530.
- 47) Gursel EO, Georgountzos C, Uson AC, Melicow MM, Veenema RJ. Penile cancer. *Urol.* 1973, 1:569-578.
- 48) Blanco-Yarosh M. Penile cancer: an overview. *Urol Nurs.* 2007, 27:286-290.
- 49) Culkun DJ, Beer TM. Advanced penile carcinoma. *J Urol.* 2003, 170:359-365.